

See discussions, stats, and author profiles for this publication at: <https://www.researchgate.net/publication/10625856>

Endovenous Laser Treatment of Saphenous Vein Reflux: Long-Term Results

ARTICLE *in* JOURNAL OF VASCULAR AND INTERVENTIONAL RADIOLOGY · SEPTEMBER 2003

Impact Factor: 2.41 · DOI: 10.1097/01.RVI.0000082864.05622.E4 · Source: PubMed

CITATIONS

301

READS

66

3 AUTHORS, INCLUDING:



Neil M Khilnani

Cornell University

59 PUBLICATIONS 1,182 CITATIONS

SEE PROFILE



Steven Zimmet

Zimmet Vein and Dermatology

32 PUBLICATIONS 807 CITATIONS

SEE PROFILE

Endovenous Laser Treatment of Saphenous Vein Reflux: Long-Term Results

Robert J. Min, MD, Neil Khilnani, MD, and Steven E. Zimmet, MD

PURPOSE: To report long-term follow-up results of endovenous laser treatment for great saphenous vein (GSV) reflux caused by saphenofemoral junction (SFJ) incompetence.

MATERIALS AND METHODS: Four hundred ninety-nine GSVs in 423 subjects with varicose veins were treated over a 3-year period with 810-nm diode laser energy delivered percutaneously into the GSV via a 600- μ m fiber. Tumescence anesthesia (100–200 mL of 0.2% lidocaine) was delivered perivenously under ultrasound (US) guidance. Patients were evaluated clinically and with duplex US at 1 week, 1 month, 3 months, 6 months, 1 year, and yearly thereafter to assess treatment efficacy and adverse reactions. Compression sclerotherapy was performed in nearly all patients at follow-up for treatment of associated tributary varicose veins and secondary telangiectasia.

RESULTS: Successful occlusion of the GSV, defined as absence of flow on color Doppler imaging, was noted in 490 of 499 GSVs (98.2%) after initial treatment. One hundred thirteen of 121 limbs (93.4%) followed for 2 years have remained closed, with the treated portions of the GSVs not visible on duplex imaging. Of note, all recurrences have occurred before 9 months, with the majority noted before 3 months. Bruising was noted in 24% of patients and tightness along the course of the treated vein was present in 90% of limbs. There have been no skin burns, paresthesias, or cases of deep vein thrombosis.

CONCLUSIONS: Long-term results available in 499 limbs treated with endovenous laser demonstrate a recurrence rate of less than 7% at 2-year follow-up. These results are comparable or superior to those reported for the other options available for treatment of GSV reflux, including surgery, US-guided sclerotherapy, and radiofrequency ablation. Endovenous laser appears to offer these benefits with lower rates of complication and avoidance of general anesthesia.

J Vasc Interv Radiol 2003; 14:991–996

Abbreviations: GSV = great saphenous vein, RF = radiofrequency, SFJ = saphenofemoral junction

LOWER-extremity venous insufficiency is a common medical condition afflicting 25% of women and 15% of men in the United States (1). Gender, pregnancy, hormones, aging, and gravitational forces from prolonged standing or sitting are the most common factors that influence the appear-

ance or worsening of primary varicose veins (2,3). Although many people seek medical treatment for varicose veins because they find them unsightly, most people with varicose veins do experience symptoms (4,5). Unfortunately, symptoms of primary venous insufficiency are often not rec-

ognized by patients or their physicians. Characteristic leg complaints associated with varicose veins include aching pain, night cramps, fatigue, heaviness, or restlessness. Symptoms arise from pressure on somatic nerves by dilated veins and are typically worsened with prolonged standing, during the premenstrual period, or in warm weather (6). Left untreated, nearly 50% of patients with significant superficial venous insufficiency will eventually experience chronic venous insufficiency characterized by lower-extremity swelling, eczema, pigmentation, hemorrhage, and ulceration (7).

Great saphenous vein (GSV) reflux is the most common underlying cause of significant varicose veins. Traditional treatment of GSV reflux has been surgical removal of the GSV. Al-

From Cornell Vascular (R.J.M., N.K.), Weill Medical College of Cornell University, 416 East 55th Street, New York, New York 10022; and Zimmet Vein and Dermatology Clinic (S.E.Z.), Austin, Texas. Received January 24, 2003; revision requested April 11; revision received May 7; accepted May 8. From the 2003 SIR Annual Meeting. **Address correspondence to** R.J.M.; E-mail: rjm2002@med.cornell.edu

R.J.M. is a consultant to Diomed (Andover, MA), assisting in development of medical treatments and physician training. R.J.M. is inventor and part owner of a patent on endovenous laser treatment of

veins, for which he receives royalties. R.J.M. and Cornell Vascular have paid for all medical equipment used in procedures relating to this study. S.E.Z. is a paid consultant to Diomed, Inc. (Andover, MA), assisting in development of medical treatments. S.E.Z. is also paid to assist in physician training. S.E.Z. purchased all medical equipment he used in connection with this study. The other author has not identified a potential conflict of interest.

© SIR, 2003

DOI: 10.1097/01.RVI.0000082864.05622.E4

though surgical ligation and stripping of the GSV has been the most durable treatment, it is associated with significant perioperative morbidity. Less-invasive surgical treatments including high ligation of the GSV at the saphenofemoral junction (SFJ) have been attempted with the hope that gravitational reflux would be controlled while the vein is preserved for possible use as a bypass graft. Unfortunately, ligation of the GSV alone usually results in recurrent varicose veins (8). Even when high ligation has been combined with phlebectomy of varicose tributaries or retrograde sclerotherapy, recurrence has been the rule (9,10). Therefore, when it is determined that GSV reflux is the principal underlying problem, treatment should involve eliminating this source of reflux with ablation of any associated incompetent venous segments.

In 1999, Boné (11) first reported on delivery of endoluminal laser energy. Since then, a method for treating the entire incompetent GSV segment has been described (12,13). Endovenous laser treatment, which received approval from the US Food and Drug Administration in January 2002, allows delivery of laser energy directly into the blood vessel lumen. Non-thrombotic vein occlusion is accomplished by heating the vein wall with 810-nm-wavelength laser energy delivered via a 600- μ m laser fiber (Diomed, Andover, MA). Sufficient heating of the vein wall is necessary to cause collagen contraction and denudation of endothelium. This stimulates vein wall thickening, eventual luminal contraction, and fibrosis of the vein. The purpose of this study is to report on the long-term follow-up results of endovenous laser treatment for GSV reflux.

MATERIALS AND METHODS

This prospective, nonrandomized, consecutive-enrollment study included 423 patients who underwent endovenous laser treatment of incompetent GSV segments with 810-nm diode laser energy delivered intraluminally for treatment of primary varicose veins. The study protocol was approved by the Weill Medical College of Cornell University Institutional Review Board. All patients gave written informed consent before treatment.

Patient Selection

Directed history and physical examination, including duplex ultrasound (US) evaluation of the superficial venous system, was performed on limbs of subjects with varicose veins. Study inclusion criteria included varicose veins caused by SFJ incompetence with GSV reflux as demonstrated by duplex US imaging, age of at least 18 years, and ability to return for scheduled follow-up examinations for 12 months after endovenous laser treatment. Exclusion criteria included nonpalpable pedal pulses; inability to ambulate; deep vein thrombosis; general poor health; pregnancy, nursing, or plans to become pregnant during the course of participation in the investigation; and extremely tortuous GSVs that would not allow endovenous catheterization and passage of the laser fiber as identified on pretreatment venous duplex US mapping. After initial consultation and evaluation, subjects meeting the appropriate criteria were offered surgery versus endovenous laser treatment. Nearly all subjects chose endovenous laser over surgical ligation and stripping.

Five hundred four incompetent GSVs were treated with endovenous laser over a 39-month period. Five limbs were lost to follow-up. The remaining 499 limbs in 423 patients comprise the study population. This group consists of 352 women (83%) and 71 men (17%) ranging in age from 23 to 72 years, with a mean age of 42 years.

Follow-up ranged from 1 month to 39 months with a mean follow-up period of 17 months and an SD of 11 months. Aching leg pain was the most common presenting symptom, found in 87% of limbs. Overall, slightly more left legs ($n = 263$, 53%) were treated, and 76 patients (18%) were treated for bilateral GSV reflux. Pretreatment GSV diameter, measured in the upright position approximately 2 cm below the SFJ, ranged from 4.4 mm to 29 mm (mean, 11 mm; SD, 4.2 mm).

None of the patients in this series underwent concomitant ambulatory phlebectomy. All but seven patients underwent compression sclerotherapy treatment of distal varicose tributaries or associated telangiectasias at follow-up visits.

Description of Technique

Duplex US was performed in the upright position to map incompetent sources of venous reflux and then to mark the skin overlying the incompetent portion of the GSV starting at the SFJ. After venous duplex mapping, a percutaneous entry point was chosen. This point may be where reflux is no longer seen or where the GSV becomes too small to access (usually just above or below knee level). With use of local anesthesia and sonographic guidance, the GSV was punctured. A 5-F introducer sheath was placed into the GSV over a guide wire and advanced past the SFJ into the femoral vein. Intraluminal position within the GSV was confirmed by aspiration of nonpulsatile venous blood and visualization with US.

The sheath was flushed and a 600- μ m laser fiber (Diomed) was inserted in the sheath and advanced up to the first site mark, indicating that the distal tip of the laser fiber was flush with the end of the sheath. The sheath was then withdrawn to the second site mark, exposing the distal 3 cm of the bare-tipped laser fiber. The sheath and fiber were pulled back together and positioned at the SFJ under US guidance. Position was confirmed by direct visualization of the red aiming beam of the laser fiber through the skin.

Tumescent local anesthesia consisting of 100–200 mL of 0.2% lidocaine neutralized with sodium bicarbonate, was administered along the perivenous space with use of US guidance. In addition to the anesthetic effects, properly delivered, this fluid serves two important functions: (1) it compresses and reduces the diameter of even the largest veins to provide vein wall apposition around the fiber tip with subsequent circumferential heating of the vein wall and (2) it provides a "heat sink" to minimize the possibility of heat-related damage to adjacent tissues. **Figure 1a** demonstrates the typical transverse sonographic appearance of the laser fiber and catheter seen centrally within an enlarged GSV located in the saphenous space. Proper and adequate delivery of tumescent anesthesia should result in fluid surrounding a compressed GSV as shown in **Figure 1b**.

The tip of the laser fiber was repo-

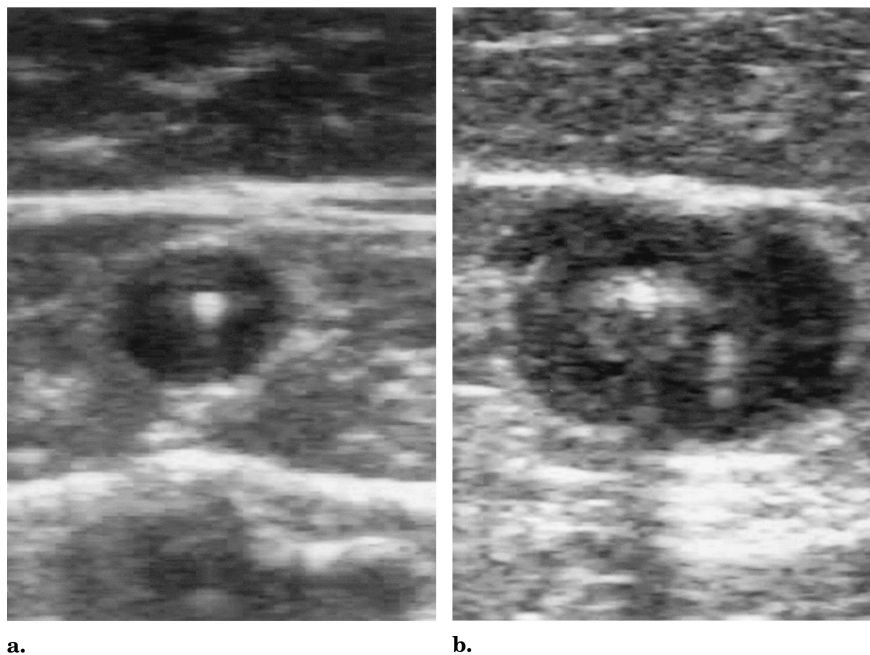


Figure 1. Duplex US (transverse view) demonstrating appearance of the GSV before and after proper delivery of tumescent anesthesia. **(a)** Intraluminal position of laser fiber and catheter within an enlarged GSV; **(b)** tumescent anesthesia delivered by echogenic needle tip adjacent to laser fiber and catheter with fluid surrounding the compressed GSV.

sitioned within the GSV 5–10 mm distal to the SFJ. Tip position was checked by US and direct visualization of the red aiming beam through the skin. Laser energy (810-nm diode laser; Diomed) was delivered at 14 W in continuous mode. The vein was treated from 5–10 mm below the SFJ to approximately 1 cm above the skin entry site. Length of GSV treated with endovenous laser ranged from 10 cm to 55 cm (mean, 35 cm; SD, 10 cm). The laser fiber was withdrawn at an average rate of 3 mm per second (18 cm per minute). Of patients treated with 14-W continuous mode ($n = 276$, or 55% of limbs), delivery of laser energy ranged from 25 seconds (at 358 J) to 187 seconds (at 2,615 J), with a mean of 123 seconds (SD, 47 sec) or 1,727 J (SD, 650 J).

A class II (30–40 mm Hg) full-thigh graduated support stocking or panty hose was worn for at least 1 week at all times except to sleep or to shower. Patients were instructed to ambulate and resume their normal daily activities immediately. Clinical and duplex US follow-up was obtained at 1 week, 1, 3, 6, 9, and 12 months, and then yearly.

Compression sclerotherapy treat-

ment of distal varicose tributaries was performed with use of sodium tetracycl sulfate (0.3%–1% concentration). A detailed description of sclerotherapy technique is beyond the scope of this article but the approach used was the “French school” originally advocated by Tournay and more recently popularized in the United States by Goldman and other phlebologists (14). This technique relies on starting from the highest points of reflux and proceeding downward, and treating veins from the largest to the smallest. Compression stockings or panty hose were worn for at least 1 week after sclerotherapy treatments except to sleep or shower. Sclerotherapy treatments were performed at 4-week intervals, starting 1 month after endovenous laser ablation of the GSV.

Study Endpoints and Definitions

Duplex US criteria for successful treatment were the following: at 1-week follow-up, an enlarged non-compressible GSV, minimally decreased in diameter, with echogenic, thickened vein walls, and no flow seen within the occluded vein lumen on color Doppler interrogation; at 3- and

6-month follow-up, an occluded GSV with substantial (>50%) reduction in diameter; and at 1 year and beyond, complete disappearance of the GSV or minimal residual fibrous cord with no flow detectable. It is important to note that the expected appearance 1–2 weeks after endovenous laser is a slightly smaller GSV demonstrating wall thickening with absence of flow within the treated vein segment. The vein lumen is usually obliterated by the thickened wall, which has low-level echoes and is incompressible. This wall thickening should be differentiated from acute GSV thrombosis wherein the vein is also incompressible but the lumen is filled with anechoic acute thrombus. Several weeks after successful endovenous laser treatment, resolution of the acute inflammation in the vein wall should result in reduction in vein diameter. After several months, most of the treated vein segments will fibrose and be difficult to identify. Alternatively, superficial thrombophlebitis with GSV thrombus would result in recanalization of the vein. A longitudinal view of an enlarged, incompetent GSV is seen in **Figure 2a**. **Figure 2b** demonstrates the typical color Doppler appearance of a successfully treated GSV 1 year after endovenous laser treatment.

Clinical evaluation was performed on all subjects at 1 week, 1, 3, 6, 9, and 12 months, and yearly thereafter by the same physician (R.M.) who performed all the endovenous laser procedures. Patients were queried about symptomatic relief at follow-up visits, particularly improvement or resolution of lower-extremity pain believed to be associated with venous insufficiency. Improvement in the appearance of the leg, including reduction in visible varicosities, swelling, pigmentation, or other skin changes secondary to chronic venous insufficiency, were assessed by the patient and with direct comparison with pretreatment photographs obtained from all subjects undergoing treatment. Patients were evaluated for possible adverse reactions caused by endovenous laser treatment at each follow-up visit. Minor complications were defined as those that had no significant clinical sequelae, such as bruising. Major complications were defined as those necessitating an increased level of care, sur-

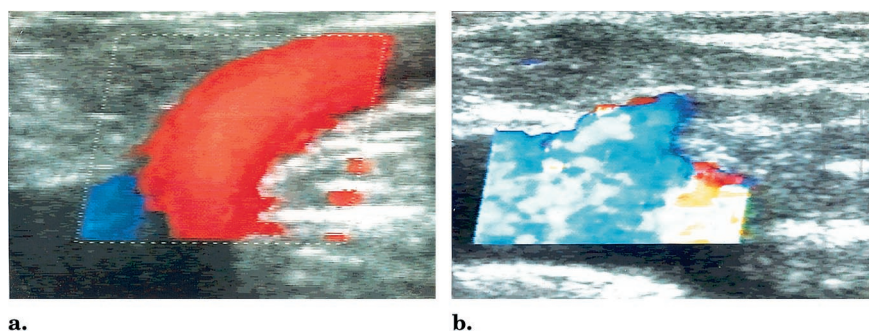


Figure 2. Color Doppler examinations (longitudinal views) of the GSV at the SFJ demonstrating successful occlusion after endovenous laser treatment. (a) Pretreatment evaluation demonstrates an enlarged GSV with reflux after distal calf compression; (b) 1-year follow-up examination shows typical "cul-de-sac" appearance of the proximal GSV with occlusion of the treated segment.

gery, hospitalization, or permanent adverse sequelae.

RESULTS

Follow-up results ranging from 1 month to 39 months (mean, 17 months; SD, 11 months) were obtained in 499 of the 504 limbs treated with endovenous laser during the study period. Successful endovenous laser treatment, as defined earlier, was seen in 490 of 499 limbs (98%) at 1-month follow-up. Eight of nine GSVs requiring repeat endovenous laser were successfully closed with a second endovenous laser treatment. Continued closure of the treated GSV segments was noted at longitudinal follow-up at the following rates: 444 of 447 (99.3%) at 3 months, 390 of 396 (98.5%) at 6 months, 351 of 359 (97.8%) at 9 months, 310 of 318 (97.5%) at 1 year, and 113 of 121 (93.4%) at 2 years. Forty subjects have been followed for 3 years and no new recurrences were seen at 2 or 3 years that were not present at 1-year follow-up. In fact, all recurrences were noted before 9 months, with the majority seen by 3 months. This may indicate that these were not true recurrences but rather inadequate initial treatments.

Clinical examination correlated well with duplex US findings. All patients showed improvement in the appearance of the limb with disappearance or reduction in the size and number of visible varicosities. The typical appearance of varicose veins caused by incompetence of the SFJ with GSV reflux is shown in **Figure 3a**.

One month after endovenous laser treatment, relief of symptoms and significant improvement in the appearance of the varicose veins was noted (**Fig 3b**). By 6 months after initial treatment, pain was greatly improved or resolved in all treated limbs. Although symptomatic resolution and significant improvement in the appearance of the leg is usually noted after endovenous laser treatment alone, most patients will need additional complementary procedures (ie, sclerotherapy or phlebectomy) to fully realize the restorative benefits of treatment.

Bruising outside the puncture site was noted in 24% of limbs at 1-week follow-up. Bruising resolved in all subjects before 1-month follow-up. Ninety percent of subjects felt a delayed tightness peaking 4–7 days after laser treatment and lasting 3–10 days. This sensation, described as "pulling" along the course of the treated GSV, was not felt in the nine patients in whom initial treatment failed. Five percent of patients developed superficial phlebitis of varicose tributaries after endovenous laser occlusion of the GSV. Most cases required no treatment. Symptomatic patients were treated with graduated compression stockings and over-the-counter antiinflammatory agents. All minor complications listed earlier resolved without sequelae. There have been no skin burns, paresthesias, cases of deep vein thrombosis, or other minor or major complications. The procedure was

well-tolerated by all subjects with strictly local anesthesia.

Overall treatment satisfaction was determined by asking subjects if they would recommend the procedure to a friend with similar leg vein problems, and 422 of 423 subjects (99.8%) indicated they would recommend the procedure.

DISCUSSION

Percutaneous methods for treating incompetent GSVs are not new. Duplex-guided sclerotherapy for treatment of GSV reflux has been attempted, but long-term studies have failed to prove durability comparable to surgery (15–19). Initial attempts at damaging vein walls by electrocoagulation involved creation of a thrombus within the vessel lumen, ultimately resulting in recanalization (20–22). Early methods of intraluminal delivery of high-frequency alternating-current radiofrequency (RF) energy to treat GSV reflux were complicated by skin burns, saphenous nerve and peroneal nerve injury, phlebitis, and wound infection (23).

A more modern technique of the use of RF energy to eliminate saphenous vein reflux has been developed by VNUS Medical Technologies (Sunnyvale, CA). Early results reported from a multicenter trial demonstrated a reasonable degree of success with an overall failure rate of 10% at a mean follow-up of 4.7 months (13% in patients treated with RF alone and 5% in patients treated with RF plus high ligation of the GSV). Complications included transient paresthesias (thigh, 9%; leg, 51%), skin burns (3%), deep venous thrombosis (3%), and one pulmonary embolus (24). More recent studies have demonstrated success rates of 73%–90% with follow-up to 24 months in 21 limbs (25–27).

One of the limitations of our study is that it does not provide a blinded, randomized comparison of the various modern percutaneous methods available for treatment of GSV reflux, including RF and wavelengths of laser energy other than 810 nm. However, review of the literature allows some comparisons and raises some interesting areas for future study.

RF current damages tissue by resistive heating of structures in direct con-

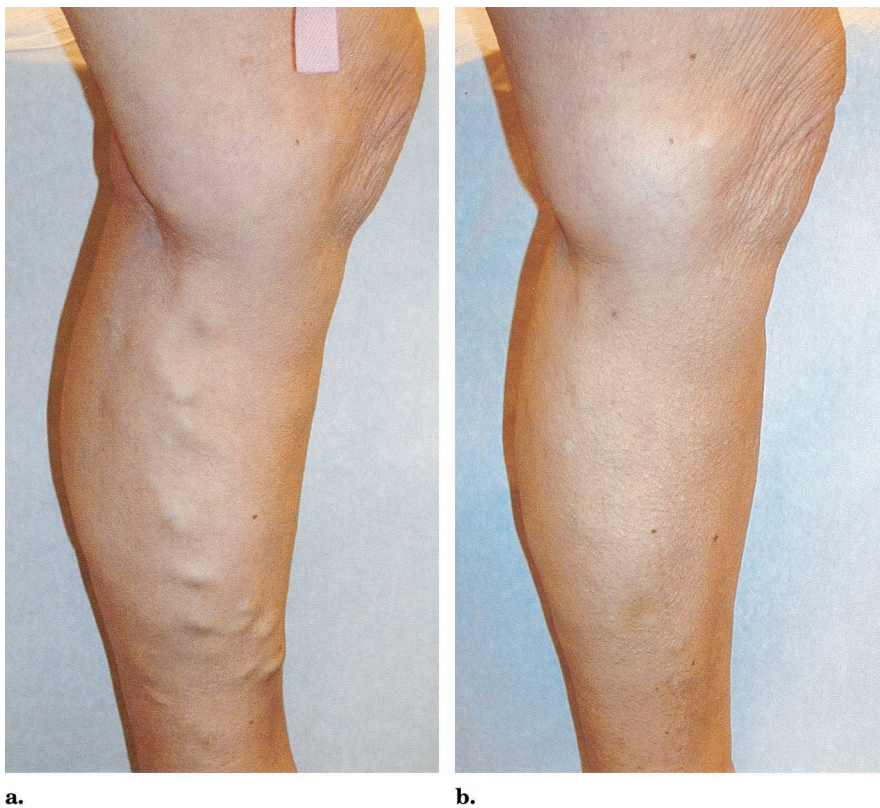


Figure 3. Significant improvement in appearance of varicose tributaries after endovenous laser treatment of an incompetent left GSV. (a) Typical appearance of varicose veins caused by GSV reflux; (b) the same leg 1 month after endovenous laser treatment.

tact with the electrodes. Deeper tissue planes are heated by conduction into normothermic tissue. Because the potential for heating of adjacent perivenous tissue is high, safe treatment with RF depends on proper delivery of adequate tumescent anesthesia. Effective use of tumescent anesthesia appears to have reduced the incidence of heat-related complications. In expert hands, the incidence of paresthesias after RF has occurred in as few as 8.5% of limbs within 1 week of treatment and decreased to 0.7% at 6 months (27). However, with less-experienced physicians, RF still has been complicated with heat-related adverse effects such as paresthesias (10% at 6 months) and skin burns (3.3%) (25).

Published experience with endovenous laser with use of wavelengths other than 810 nm is limited. A recent study by Chang and Chua (28) reported the use of 1,064-nm laser energy delivered endovenously for treatment of GSV reflux. Although this study reported a success rate of 96.8%

in 244 legs followed up to 28 months, significant complications were noted, including paresthesias (36.5%) and skin burns (4.8%). In addition to endovenous laser ablation, all patients in their study underwent surgical ligation and division of the proximal and distal ends of the treated GSV. In addition, patients treated with the 1,064-nm wavelength underwent spinal or general anesthesia rather than strictly local tumescent anesthesia (28).

In comparison, in our series of more than 500 limbs treated with 810-nm diode laser energy delivered endovenously, there have been no heat-related complications despite the high temperatures attained at the laser fiber tip. This may be explained by the following: (1) improved delivery and use of sufficient amounts of tumescent fluid in the proper tissue plane providing a protective thermal "sink;" (2) selective, homogeneous, and circumferential heating of the inner vein wall by absorption of 810-nm laser energy by blood lining the vein wall, as noted

in a recent study by Proebstle et al (29), rather than deeper penetration of laser energy and less-homogeneous heating from endovenous laser performed with wavelengths such as 1,064 nm, which are absorbed less by blood and more by water; and (3) faster rates of withdrawal and shallower depth of penetration of 810-nm laser energy, resulting in less damage to surrounding nontarget tissue compared with methods that use RF.

It has been suggested that a randomized controlled trial comparing outcomes of endovenous laser ablation of the saphenous vein to surgical ligation and stripping should be performed; however, such a study would be difficult given patients' overwhelming desire for minimally invasive treatments rather than surgery. Review of the existing surgical literature does provide some insight in assessing treatment durability. Multiple studies have shown that recurrence of varicose veins after GSV stripping occurs early (30), with 73% of limbs destined for recurrent varicosities at 5 years already having them at 1 year (31,32). Our results with endovenous laser have supported this, demonstrating that what is found on duplex imaging early is predictive of what will be seen later, with none of the treated patients developing recanalization of successfully occluded GSVs at 2 or 3 years that was not seen before 9 months.

Performing endovenous ablation of the GSV without dissection of the SFJ violates a cardinal rule in saphenous vein surgery that each of the tributaries must be individually divided. Surprisingly, the combined experiences with transcatheter endovenous ablation procedures have shown lower recurrence rates than with surgical ligation and stripping. Perhaps minimizing dissection in the groin and preserving venous drainage in normal, competent tributaries while removing only the abnormal refluxing segments does not incite neovascularization.

The understanding of venous disorders continues to improve with tremendous strides being made over the past decade. Readily available noninvasive diagnostic tests allow physicians to precisely map out abnormal venous pathways and identify sources of incompetence. Modern percutaneous methods of sealing incompetent veins

provide patients with alternatives to ligation and stripping for treatment of GSV reflux without the familiar morbidities associated with surgery (33,34). Given these recent advances, many physicians, when properly trained, will now be able to successfully diagnose and treat the whole spectrum of superficial venous insufficiency, offering acceptable options to the millions of people in the United States alone who have varicose veins but are unwilling or unable to undergo surgery.

References

- Callam MJ. Epidemiology of varicose veins. *Br J Surg* 1994; 81:167-173.
- Rose SS. Anatomic observations on causes of varicose veins. In: Goldman MP, Weiss RA, Bergan JJ, eds. *Varicose veins and telangiectasia: diagnosis and treatment*. St Louis: Quality Medical Publishing, 1999; 12-17.
- Goldman M. Pathophysiology of varicose veins. In: Goldman M, ed. *Sclerotherapy: treatment of varicose and telangiectatic leg veins*. St. Louis: Mosby-Year Book, 1995; 85-117.
- Weiss R, Weiss M. Resolution of pain associated with varicose and telangiectatic leg veins after compression sclerotherapy. *J Dermatol Surg Oncol* 1990; 16:333-336.
- Wilder CS. Prevalence of selected chronic circulatory conditions. *Vital Health Stat* 1974; 10:1-55.
- Fegan WG, Lambe R, Henry M. Steroid hormones and varicose veins. *Lancet* 1967; 2:1070-1071.
- Widmer LK, Mall TH, Martin H. Epidemiology and social medical importance of diseases of the veins. *Munch Med Wochenschr* 1974; 116:1421-1426.
- McMullin GM, Smith PDC, Scurr JH. Objective assessment of high ligation without stripping the long saphenous vein. *Br J Surg* 1991; 78:1139-1142.
- Stonebridge PA, Chalmers N, Beggs I, Bradbury AW, Ruckley CV. Recurrent varicose veins: a varicographic analysis leading to a new practical classification. *Br J Surg* 1995; 82:60-62.
- Rutgers PH, Kitslaar PJEHM. Randomized trial of stripping versus high ligation combined with sclerotherapy in the treatment of incompetent greater saphenous vein. *Am J Surg* 1994; 168:311-315.
- Boné C. Tratamiento endoluminal de las varices con laser de diodo: estudio preliminar. *Rev Patol Vasc* 1999; 5:35-46.
- Navarro L, Min R, Boné C. Endovenous laser: a new minimally invasive method of treatment for varicose veins-preliminary observations using an 810 nm diode laser. *Dermatol Surg* 2001; 27:117-122.
- Min R, Zimmet S, Isaacs M, Forrestal M. Endovenous laser treatment of the incompetent greater saphenous vein. *J Vasc Interv Radiol* 2001; 12:1167-1171.
- Cornu-Thenard A, Boivin P. Treatment of varicose veins by sclerotherapy: an overview. In: Goldman M, Weiss R, Bergan J, eds. *Varicose veins and telangiectasias: diagnosis and treatment*, second edition. St. Louis: Quality Medical Publishing, 1999; 225-246.
- Bishop CC, Fronek HS, Fronek A, Dillely RB, Bernstein EF. Real-time color duplex scanning after sclerotherapy of the greater saphenous vein. *J Vasc Surg* 1991; 14:505-510.
- Cornu-Thenard A, de Cottreau H, Weiss RA. Sclerotherapy: continuous-wave Doppler-guided injections. *Dermatol Surg* 1995; 21:867-870.
- Kanter A. Clinical determinants of ultrasound-guided sclerotherapy outcome. Part I: the effects of age, gender, and vein size. *Dermatol Surg* 1998; 24:131-135.
- Kanter A. Clinical determinants of ultrasound-guided sclerotherapy outcome. Part II: the search for the ideal injectate volume. *Dermatol Surg* 1998; 24:136-140.
- Belcaro G, Nicolaidis AN, Ricci A, et al. Endovascular sclerotherapy, surgery, and surgery plus sclerotherapy for superficial venous incompetence: a randomized 10-year follow-up trial: final results. *Angiology* 2000; 51:529-534.
- Politowski M, Szpak E, Marszalek Z. Varices of the lower extremities treated by electrocoagulation. *Surgery* 1964; 56:355-360.
- Watts GT. Endovenous diathermy destruction of internal saphenous. *BMJ* 1972; 4:53.
- O'Reilly K. Endovenous diathermy sclerosis of varicose veins. *Aust N Z J Surg* 1977; 47:393-395.
- Politowski M, Zelazny M. Complications and difficulties in electrocoagulation of varices of the lower extremities. *Surgery* 1966; 59:932-934.
- Manfrini S, Gasbarro V, Danielsson G, et al. Endovenous management of saphenous vein reflux. *J Vasc Surg* 2000; 32:330-342.
- Rautio TT, Perala JM, Wiik HT, Juvonen TS, Haukipuro KA. Endovenous obliteration with radiofrequency-resistive heating for greater saphenous vein insufficiency: a feasibility study. *J Vasc Interv Radiol* 2002; 13:569-575.
- Merchant RF, DePalma RG, Kabnick LS. Endovascular obliteration of saphenous reflux: a multicenter study. *J Vasc Surg* 2002; 35:1190-1196.
- Weiss RA, Weiss MA. Controlled radiofrequency endovenous occlusion using a unique radiofrequency catheter under duplex guidance to eliminate saphenous varicose vein reflux: a 2-year follow-up. *Dermatol Surg* 2002; 28:38-42.
- Chang C, Chua J. Endovenous laser photocoagulation (EVLP) for varicose veins. *Lasers Surg Med* 2002; 31:257-262.
- Proebstle TM, Sandhofer M, Kargl A, et al. Thermal damage of the inner vein wall during endovenous laser treatment: key role of energy absorption by intravascular blood. *Dermatol Surg* 2002; 28:596-600.
- Sarin S, Scurr JH, Smith PDC. Assessment of stripping of the long saphenous vein in the treatment of primary varicose veins. *Br J Surg* 1992; 79:889-893.
- Dwerryhouse S, Davies B, Harradine K, Earnshaw JJ. Stripping the long saphenous vein reduces the rate of reoperation for recurrent varicose veins: five-year results of a randomized trial. *J Vasc Surg* 1999; 29:589-592.
- Jones L, Braithwaite BD, Selwyn D, Cooke S, Earshaw JJ. Neovascularization is the principal cause of primary vein recurrence: results of a randomized trial of stripping the long saphenous vein. *Eur J Vasc Endovasc Surg* 1996; 12:442-445.
- Miller GV, Lewis WG, Sainsbury JR, MacDonald RC. Morbidity of varicose vein surgery: auditing the benefit of changing clinical practice. *Ann R Coll Surg Engl* 1996; 78:345-349.
- Mackay DC, Summerton DJ, Walker AJ. The early morbidity of varicose vein surgery. *J R Nav Med Serv* 1995; 81:42-46.